

J Oral Maxillofac Surg
60:576-579, 2002

Severe Facial Ischemia After Endodontic Treatment

Peter Lindgren, MD, DDS, Karl-Fredrik Eriksson, MD, PhD,†
and Anita Ringberg, MD, PhD‡*

*Consultant, Department of Oral and Maxillofacial Surgery, Lund University, Malmö University Hospital, Malmö, Sweden.

†Associate Professor, Department of Vascular Diseases, Lund University, Malmö University Hospital, Malmö, Sweden.

‡Associate Professor, Department of Plastic Surgery, Lund University, Malmö University Hospital, Malmö, Sweden.

Address correspondence and reprint requests to Dr Lindgren:
Department of Oral and Maxillofacial Surgery, University Hospital,
S-221 85 Lund, Sweden; e-mail: peter.lindgren@skane.se

© 2002 American Association of Oral and Maxillofacial Surgeons

0278-2391/02/6005-0019\$35.00/0

doi:10.1053/joms.2002.31861

Calcium hydroxide is a well known temporary root canal dressing. It has been considered a safe agent, with good bacteriostatic characteristics and low toxicity. We report the case of a patient with an adverse reaction after calcium hydroxide extrusion during endodontic therapy.

Report of a Case

At his first appointment a 48-year-old man underwent endodontic instrumentation of the vital right mandibular second molar. Before the optimal depth of instrumentation was determined with a radiograph, abnormal bleeding occurred from the distal root canal, which was considered to

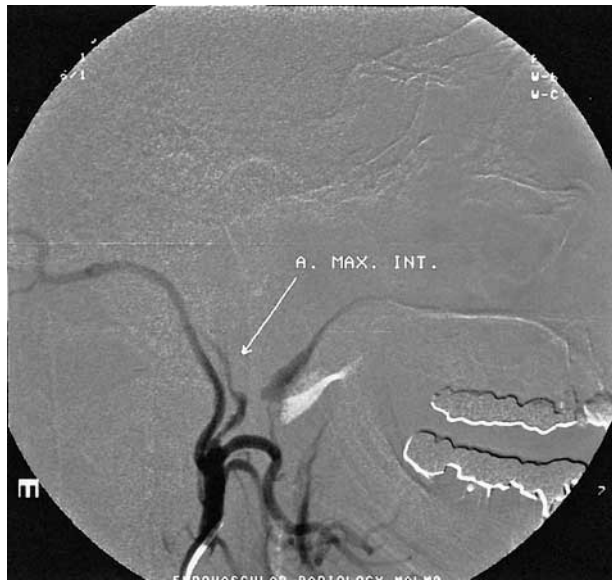

FIGURE 1. Angiogram showing no blood flow in the right maxillary artery.

be an indication of apical perforation. After completion of the instrumentation, the application of an absorbent paper point produced new profuse bleeding from the distal canal. Two mesial canals were dressed with calcium hydroxide paste (Calasept; Nordiska Dental, Ängelholm, Sweden). The bleeding from the distal canal stopped, and calcium hydroxide paste was then applied. When the paste was applied with a syringe in the distal canal, the patient experienced severe local pain. In about 1 or 2 minutes, the corresponding half of the face became pale. During the following 90 minutes, the right half of the face, including the ear, became increasingly cyanotic in combination with increasing pain. Part of the palate, corresponding to the right greater palatine foramen, also became cyanotic. Facial nerve paralysis and trigeminal paresthesia developed in all branches of the right side. Vision in the right eye became blurry. During the progression of symptoms, the patient was admitted to the emergency department of the university hospital, where an ear, nose, and throat specialist, a plastic surgeon, and a maxillofacial surgeon examined the patient. A magnetic

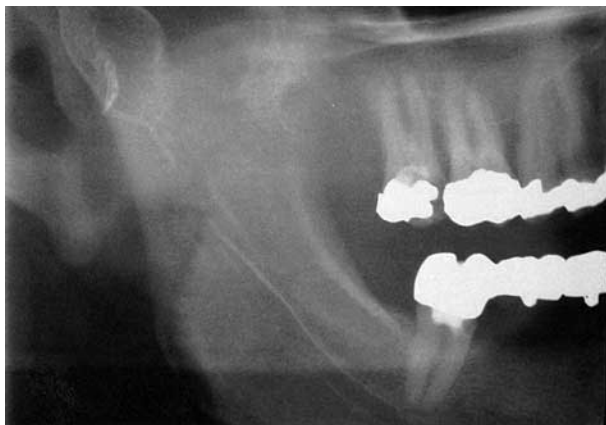

FIGURE 2. Part of a panoramic radiograph showing the radiopaque calcium hydroxide in the inferior alveolar artery.

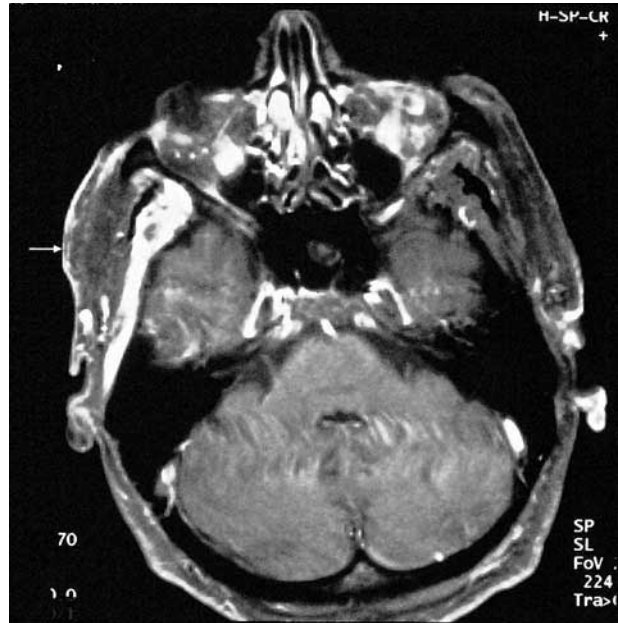

FIGURE 4. Magnetic resonance image showing edema (arrow) in the right temporal muscle demarcated by a hyperemic zone.

resonance imaging examination was started but could not be completed because of claustrophobia.

The patient was then admitted to the ear, nose, and throat ward for observation, with a preliminary diagnosis of vasculitis. The pain in the entire right side of the face increased to a level making treatment with high-dose morphine necessary. Angiography was performed, which showed a number of vascular occlusions of vessels of the right external carotid artery distribution (Fig 1). A diagnosis of thromboembolism was made. An attempt at thrombolysis with recombinant human tissue-type plasminogen activator, (Actlyse; Boehringer Ingelheim GmbH, Ingelheim am Rhein, Germany) was not successful according to laser Doppler blood flow measurement. It became clear that the only likely explanation for the symptoms was that calcium hydroxide had been introduced into the inferior alveolar artery via the distal root canal of tooth 47 and farther into the maxillary and external carotid arteries. This was confirmed with a panoramic radiograph, which showed radiopacities in the mandibular canal posterior to the distal apex of tooth 47 (Fig 2). The paste had then been transported as multiple emboli by the bloodstream. The angiograph showed multiple radiopacities in arteries of the external carotid system, supporting this theory. This phenomenon was earlier called "hand trip," in connection with intra-arterial distribution of the drug secobarbital sodium, causing peripheral necrosis.¹ Examination of the blood flow via laser Doppler showed that the ischemia was severe (Fig 3). It became likely that particles had reached the capillary bed; otherwise, collaterals would have made the situation less destructive. Treatment with iloprost (Ilo-medin; Schering AG, Berlin, Germany), a prostacycline analog, was started to increase the capillary blood flow. A new laser Doppler examination did not show any significant improvement after the first iloprost infusion. Because of clinical signs of improvement, the treatment was continued for 4 weeks, such as it is used for Bùrgers' disease (thromboangiitis obliterans).

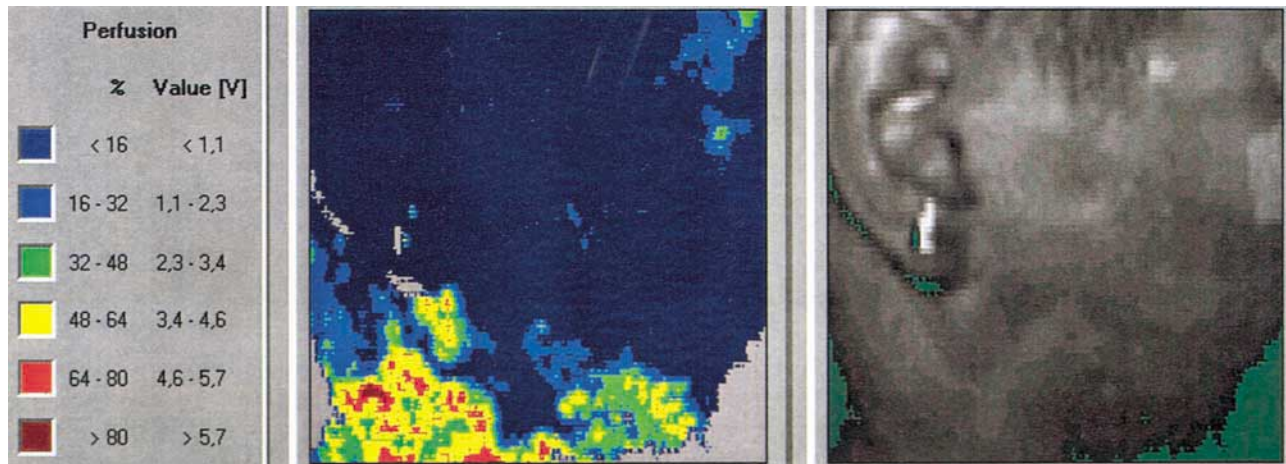


FIGURE 3. Laser Doppler examination showing ischemia of the right side of the face. The darkest regions represent perfusion of less than 16%.

During the first week after the incident, the cyanosis decreased and was replaced by signs of necrosis of the skin in the right frontal and temporal region, cheek, and inferior part of the ear. The color of the rest of the face returned to normal. Paralysis and paresthesia of the first week showed regression, and vision returned to normal after the first day. The temporal and masseteric muscles became atrophic. A new magnetic resonance imaging study was performed, which showed edema in several locations, including centrally in the temporal and masseteric muscles, as a sign of impaired circulation (Fig 4). When the patient opened his mouth, the mandible deviated to the right side and no

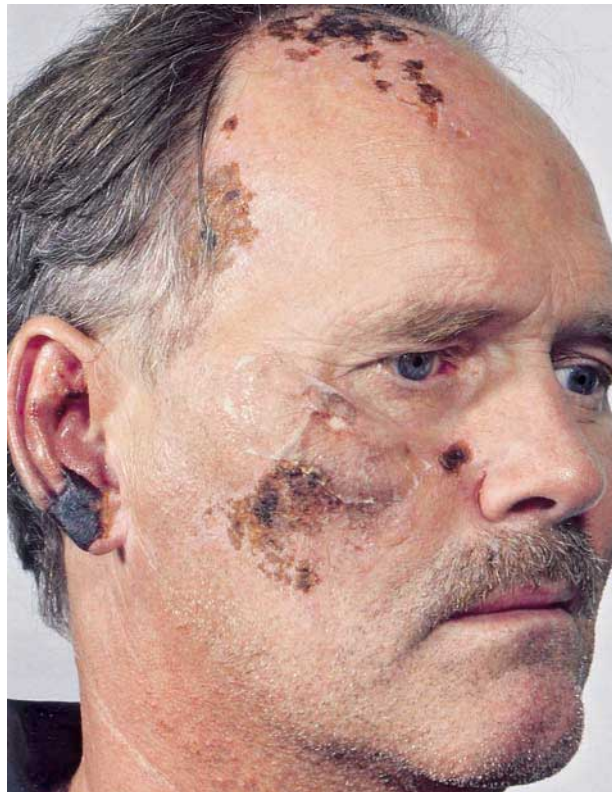

FIGURE 5. A view of the necrotic regions of the skin as they appeared after 3 weeks.

translation was palpable in the right temporomandibular joint, as a sign of paralysis of the lateral pterygoid muscle. During the following weeks, the necrotic regions of the skin became increasingly well defined (Fig 5). Necrotic bone and soft tissue were removed from the right cavity of the nose, with signs of septal perforation at the right side. The facial paralysis continued to decrease. The initially cyanotic part of the palate became necrotic, and the underlying bone was sequestered (Fig 6). Most of the teeth in the right side were tender on chewing, but showed no signs of mobility. None of the presumably vital teeth of the right side of both jaws demonstrated vitality when tested with a pulp tester. The patient experienced a burning feeling in the mucous membranes, making eating painful.

During the following 3 to 4 months, the patient improved in several locations. The facial paralysis was completely resolved. Permanent loss of mandibular nerve function was obvious by the total absence of activity in the inferior alveolar and mental nerve. The rest of the trigeminal nerve paresthesia was recovered. Paralysis of the lateral pterygoid muscle suddenly disappeared after 3 months, making it

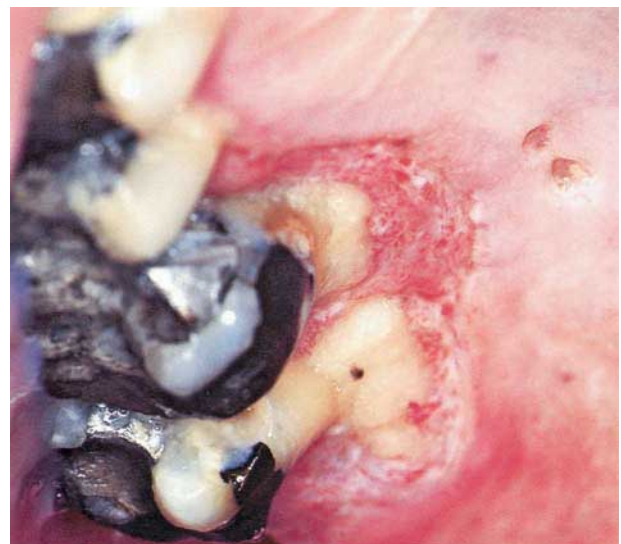

FIGURE 6. A view of the sequestered bone in the right side of the palate.

possible to translate the mandible in both directions. The skin healed spontaneously with pale scars. Necrosis of the inferior part of the ear required a full-thickness skin graft. Signs of septal perforation of the nose did not occur but healed. The burning feeling in the oral mucosa disappeared, and the necrotic part of the palate healed, leaving partially exposed root surfaces of teeth 16 and 17. The majority of the initially vital teeth showed no or doubtful sensibility on electrical stimulation. The region of pain in the face decreased continuously and after 2 months was located to the forehead and behind the nose. After 4 months, the remaining pain had the character of an ordinary headache. During the first weeks, the patient developed signs of depression, which improved after a combination of psychologic and pharmacologic treatment.

Discussion

In this case, four factors combined in an unfortunate way: 1) anatomically, the root canal came into direct contact with the mandibular canal, 2) overinstrumentation of the root canal occurred, 3) the root canal paste was distributed with the syringe, and 4) calcium hydroxide paste was used, which is a highly toxic substance due to its physiological properties and high pH (12.4).

Of these factors, the anatomic location is, of course, not possible to influence, but it is important to take the anatomic structures in consideration, as in all other forms of medical treatment.² The overinstrumentation of the root canal established a communication to the inferior alveolar artery and, for that reason, a communication farther to the external carotid artery, which supplies the face and the oral cavity mainly via the maxillary, facial, and superficial temporal arteries. In this case, the syringe probably entered the root canal deep enough to increase pressure, sufficiently high to exceed the arterial blood pressure, making it possible to distribute the paste upstream. After the paste entered the maxillary and external carotid arteries, it simply followed the bloodstream distally and was spread out into the capillary

bed. This is based on the assumption that the volume of the calcium hydroxide paste particles was sufficiently low to permit entrance into the capillaries. This is the only likely explanation because of the extremely severe ischemia. A contributing factor is probably the toxicity of the paste. Cytotoxic cell destruction caused by calcium hydroxide, among other dental materials, has been reported by Murray et al.³ Brodin and Orstavik⁴ described the neurotoxic effects of Calasept. Extended inflammatory damaging reactions on connective tissue caused by calcium hydroxide are described by Nelson et al.⁵

The importance of implanting alloplastic substances in the human body with respect as to their biology and precautions is obvious, as well as the development of new materials with high biocompatibility.⁶ The technique of endodontic filling is also worth noting in this case. It has been shown that the Lentulo spiral is most effective in carrying the paste to working length.⁷ The use of the syringe is a less-exacting means of delivering the filling material.

References

1. Gay GR: Intra-arterial injection of secobarbital sodium into the brachial artery: Sequelae of a "hand trip." *Anesth Analg* 50:979, 1971
2. Koçkapan C: Überfüllung in den mandibularkanal als endodontische komplikation. *Schweiz Monatsschr Zahnmed* 103:20, 1993
3. Murray PE, Lumley PJ, Ross HF, et al: Tooth slice organ culture for cytotoxicity assessment of dental materials. *Biomaterials* 21: 1711, 2000
4. Brodin P, Orstavik D: Effects of therapeutic and pulp protecting materials on nerve transmission in vitro. *Scand J Dent Res* 91:46, 1983
5. Nelson FP, Silva LA, Leonardo MR, et al: Connective tissue responses to calcium hydroxide-based root canal medicaments. *Int Endod J* 32:303, 1999
6. Geurtsen W, Leyhausen G: Biological aspects of root canal filling materials: Histocompatibility, cytotoxicity and mutagenicity. *Clin Oral Invest* 1:5, 1997
7. Sigurdsson A, Stancill R, Madison S: Intracanal placement of Ca(OH)₂: A comparison of techniques. *J Endod* 18:367, 1992